

ACTINIC CHEILITIS (“SAILOR’S LIPS”): A REVIEW FOR THE CLINICIAN

QUEILITE ACTÍNICA (“LÁBIOS DE MARINHEIRO”): UMA REVISÃO PARA O CLÍNICO

Maria Vitória de Matos¹, Julia Honorato², Ana Flávia Schueler de Assumpção Leite³,
Sílvia Paula de Oliveira⁴, Simone de Queiroz Chaves Lourenço³

ABSTRACT

Actinic Cheilitis (AC), also known as “sailor’s lips”, is a premalignant pathology, and although it is easy to diagnose and prevent, late diagnosed cases may progress to lip carcinoma. Since its main etiological factor is exposure to ultraviolet rays, individuals often exposed to the sun, including military personnel, can be considered a risk group for the disease. The aim of this study was to describe the main risk and prognostic factors of AC and to create a clinical protocol for dental surgeons, making easier to identify and conduct each case. For this purpose, a search for articles relevant to the topic was carried out in Medline, Lilacs, SciELO and PubMed databases, from 1987 to 2022. The following AC patient profile was identified: male, in the fifth decade of life, fair skinned, with lesions on the lower lip and with a long history of outdoor occupational activities/intense sun exposure. The dentist has a fundamental role in identifying risk groups, early recognition of the disease and in more advanced cases, making the correct diagnosis and recommendation to specialized care.

Keywords: Actinic Keratoses, Lip Neoplasms, Precancerous Conditions, Squamous Cell Carcinoma, Solar Cheilitis

RESUMO

A Queilite Actínica (QA), também conhecida como “lábios de marinheiro”, é uma patologia com potencial de malignização e, ainda que seja de fácil diagnóstico e prevenção, casos diagnosticados tardiamente podem evoluir para carcinoma de lábios. Seu principal fator etiológico é a exposição aos raios ultravioletas, e por este motivo, indivíduos que se expõem muito ao sol, incluindo militares, podem ser considerados grupo de risco para a doença. O objetivo principal deste trabalho foi descrever os principais fatores de risco e prognósticos da QA e apresentar uma revisão para o cirurgião-dentista, facilitando a identificação e conduta. Para tal, foi realizada busca de artigos pertinentes ao tema nas bases de dados Medline, Lilacs, SciELO e PubMed, de 1987 a 2022. O seguinte perfil do paciente com QA foi identificado: homem, na quinta década de vida, pele clara, com lesões no lábio inferior e com histórico de longo tempo de atividades ocupacionais ao ar livre/intensa exposição solar. O cirurgião-dentista possui papel fundamental na identificação dos grupos de risco, no reconhecimento precoce da doença e, em casos mais avançados, realizar o diagnóstico e o correto encaminhamento para atendimento especializado.

Palavras-chave: Carcinoma de Células Escamosas, Ceratose Actínica, Lesões Pré-Cancerosas, Neoplasias Labiais

¹Resident in Oral and Maxillofacial Traumatology at the Federal University of Rio de Janeiro (UFRJ), Rio de Janeiro, Brazil.

²Dental Surgeon, Navy Expeditionary Medical Unit, São Gonçalo, Rio de Janeiro, Brazil.

³PhD professor, Federal Fluminense University, Niteroi, Rio de Janeiro, Brazil.

⁴PhD professor, Federal University of Rio de Janeiro, Rio de Janeiro, Brazil.

How to cite this article: Matos MV, Honorato J, Leite AFSA, Oliveira SP, Lourenço SQC. Actinic cheilitis (“sailor’s lips”): a review for the clinician. *Nav Dent J.* 2023;50(2): 39-45.

Received: 06/06/2023

Accepted: 07/09/2023

INTRODUCTION

Oral cavity cancer (OCC) is one of the most common cancers in Brazil. According to the National Cancer Institute of Brazil (INCA), the estimated number of new cases of CCO in the country, for each year of the three-year period from 2023 to 2025, is 15,100 cases, corresponding to an estimated risk of 6.99 per 100,000 inhabitants, being 10,900 in men and 4,200 in women (1). The labial location is one of the most common locations for OCC (1), and authors report that there are lesions that have a higher risk of malignancy and precede the appearance of OCC, the so-called "Potentially malignant oral disorders". Actinic cheilitis is included in this group (2-5).

The appearance of actinic cheilitis (AC), also known as "sailor's lips", is associated with sun exposure, but there are other associated factors that can contribute to its development, such as smoking and drinking alcohol (5,6). The intensity and time of exposure to the sun, physical characteristics, such as fair skin tone associated with occupational activities carried out outdoors, increase the chances of developing the disease (6,7).

The marine population, in this context, needs greater dentistry care mainly regarding stomatology assessment. The lips must always be checked, due to the great exposure of soldiers to outdoor tactical activities, for long periods and on a recurring basis, in addition to mandatory physical activity, so that they are excessively exposed to the harmful effects of the sun (8).

Current evidence on the actual rates of malignant transformation of AC is limited, mainly due to the few studies and different methodologies applied, showing that AC is clinically important, but a relatively neglected condition (9). The absence of symptoms leads many patients not to bother to investigate it and professionals, in turn, end up delaying the definitive diagnosis because they do not suspect the injury and treat it clinically as an inflammatory process (10).

The aim of this literature review was to describe the main risk factors and prognoses of AC, generating a review that facilitates the dentist's identification and clinical management, besides to promote prevention measures and guidance for risk groups.

MATERIALS AND METHODS

To this review, a bibliographic search was carried out in the Medline, Lilacs, SciELO and PubMed databases. As inclusion criteria, articles published between 1987 and 2023, in English, Portuguese and Spanish, and which had an abstract available,

were selected. The descriptors used were "actinic cheilitis" and/or "solar keratosis" and/or "sailor lips". After a first selection, according to the descriptors, the abstracts were read to define the relevance of the texts. Articles that did not address the topic and whose final version was unavailable for consultation were excluded. Herein, a total of 40 articles were included in this literature review.

LITERATURE REVIEW

Epidemiology

AC is an inflammatory condition of the lips, which appears directly associated with sun exposure. The classic demographic profile of patients at high risk of AC is men over 50 years of age, fair skin, and with a long period of sun exposure, with the lower lip being the most affected site (11-13).

Risk factors and prognostic for actinic cheilitis

Sun Exposure

Historically, AC has been recognized as more prevalent in outdoor workers (farmers, fishermen and professions that are directly exposed to the sun), especially in hot and dry regions, due to its direct correlation with sun exposure (14,15). It is stated that the longer the exposure time, the greater the severity of AC in individuals exposed to ultraviolet radiation rays (UV) (16).

UV is, unquestionably, a factor related to AC (11,12), and the probability of malignancy may be higher when this exposure is associated with carcinogenic factors, such as alcohol and tobacco, becoming more pronounced in cigarette smokers due to the heat generated by burning tobacco and the absorption of its toxic products through the mucosa (11,17,18). Furthermore, there is increased susceptibility among patients with certain genetic disorders (e.g., xeroderma pigmentosum, albinism and porphyria cutanea tarda) and/or immunosuppression, and they should be alert to a possible progression to Squamous Cells Carcinoma (SCC) (19).

Inadequate use of photoprotection can make individuals more susceptible to the onset of AC. The use of a cap as a form of protection, and not a wide-brimmed hat, is only effective for the upper and middle third of the face, favoring the direct incidence of ultraviolet rays on the lips. Moreover, because they believe they are protected against radiation, individuals often disregard the importance of using sunscreen and lip balm (11,20).

Anatomic site

Authors report that 95 to 100% of AC cases occur in the lower lip (11,12) due to its greater direct exposure to sunlight, when compared to the upper lip (14,21). Lips are highly susceptible to actinic keratosis and the harm caused by exposure to UV radiation because their protection mechanisms against radiation are reduced compared to the skin: thinner keratin thickness in the region, thin epithelial layer, little amount of melanin and decreased secretion of sebaceous and sweat glands (10,16,20).

Sex, age, and skin color

Childhood is the most vulnerable phase to the effects of the sun, and excessive exposure during the first years of life increases the risk of cancer (1). The effects of radiation are cumulative, and the slow and asymptomatic progression of AC makes this injury being considered a normal condition of aging (22). The average age of diagnosis of AC is 40 years, but studies can be found that point to the fifth decade of life as the most common for diagnosis, due to the chronic nature of the disease (17,18,21).

Some studies show that women may be less likely to experience AC due to the use of lipstick, which may partially protect the lips from the sun, and the habit of using sunscreen and lip balm (17,23). On the other hand, the use of sunscreen is not frequent among males (24). In this sense, studies in specific populations, such as rural workers and fishermen, have shown a higher prevalence of cases in men, due to their occupation (16,21).

The different prevalence of cases between the sexes can still be explained by the fact that AC is normally an asymptomatic lesion and males take longer to seek dental treatment, generally showing less self-care, thus only fewer lesions end up being detected in their early stages. (21,25–27).

Individuals with fair skin color have a higher prevalence of injuries (24, 28). The absence of melanin predisposes to the appearance of lesions, as it plays a preponderant role in protecting against UV rays (28). The incidence of AC may be higher than expected in some darker-skinned individuals, but this is almost always related to high-risk occupational and recreational exposure (24).

A retrospective analysis carried out at the stomatology clinic of the Navy Dental Clinic of Brazil verified the prevalence of AC in 1,057 individuals treated at the institution, mainly in

military personnel with continuous exposure to ultraviolet radiation. The study found 29 patients diagnosed with AC, with a predominance of males, Caucasians, with an average age over 40 years old and with lesions located on the upper lip. Such findings corroborate the pattern of clinical characteristics found in the patient with AC in the other studies analyzed (29).

Education, income, and occupation

In the Brazilian population, men with low income and low education are generally more affected by AC. The higher prevalence in men is due to occupational exposure: men with low education and low income seek their livelihood in jobs that require greater resistance and physical vigor, including jobs that demand greater exposure to the sun and high temperatures (13, 25).

Occupation can contribute to the appearance and progression of injuries, as well as enabling individuals to develop habits such as smoking, alcohol consumption and chronic exposure to the sun (14). Occupations are those related to the outdoors, such as farmers, fishermen (14,15), sailors, farmers (19) and professions with direct exposure to the sun, especially in hot and dry regions (14,15).

Habits

For some authors, the role of drinking alcohol and smoking is still controversial in the literature, both for the emergence of precancerous lesions and for SCC. However, it is known that lips are directly exposed to tobacco carcinogens and that the association of smoking with occupational exposure can contribute to the development of AC (12,32). Alcohol and tobacco predispose to the appearance of this pathology because of the heat generated by burning tobacco and the absorption by the mucosa of its toxic products (12,14,15).

It is known that, for the development of AC, there is a cumulative effect of different attacks over long periods (25). When analyzed separately, the habits “alcohol use” or “tobacco use” do not present significant correlations with the presence of AC (25,26). However, when these habits are evaluated together, “alcohol and tobacco use”, a significant association with the presence of the lesion can be verified (33). It is important to report that some studies indicate a positive association between the presence of AC and sports that require continuous exposure to the sun, such as in runners and cyclists (34).

Clinical appearance and histopathological alterations

Intense sun exposure for a short period of time triggers an acute superficial inflammation of the lips, which is characterized by the presence of some elevations, dryness and swelling of the lower lip, without dysplastic changes in the epithelium though (13,33). When prolonged and high-intensity exposure to UV radiation occurs, changes occur that appear as multiple white areas, with zones of epithelial atrophy and erythema, thickening of the lip, loss of definition of the boundary between the skin and the semi-mucosa, eventually accompanied by fissures, scales and ulcers (13,18,33,34). Eventually, chronic ulceration may develop, lasting months and later progressing to SCC (18).

There is a gap regarding the classification of the AC stage at the time of diagnosis and the right time for intervention. Although the diagnosis is basically made based on clinical characteristics, biopsy must be indicated to exclude the possibility of malignant transformation (35).

To support the clinician in deciding whether or not to use an invasive therapeutic approach,

several authors have been creating classifications for AC (14, 36). In 2017, a classification was created, which divides the evolution of the disease into 4 categories, based on AC descriptions made by classic and contemporary authors of the pathology (35).

The classification by Poitevin et al., 2017 (clinically represented in Figure 1) is presented as follows:

- Grade I: dryness and peeling of the red lips;
- Grade II: Atrophy at the vermilion border, presenting soft surfaces and pale areas with rashes. Beginning of loss of definition of the redness of the lip with the skin, or a dark line demarcating this limit can be seen;
- Grade III: Rough and scaly areas in the driest parts of the vermilion of the lip and hyperkeratotic areas, especially at the limit between the labial mucosa and semi-mucosa;
- Grade IV: Ulceration present in one or more locations on the vermilion of the lip or leukoplastic area, especially in locations more susceptible to trauma. Lesions may suggest progression to malignancy.

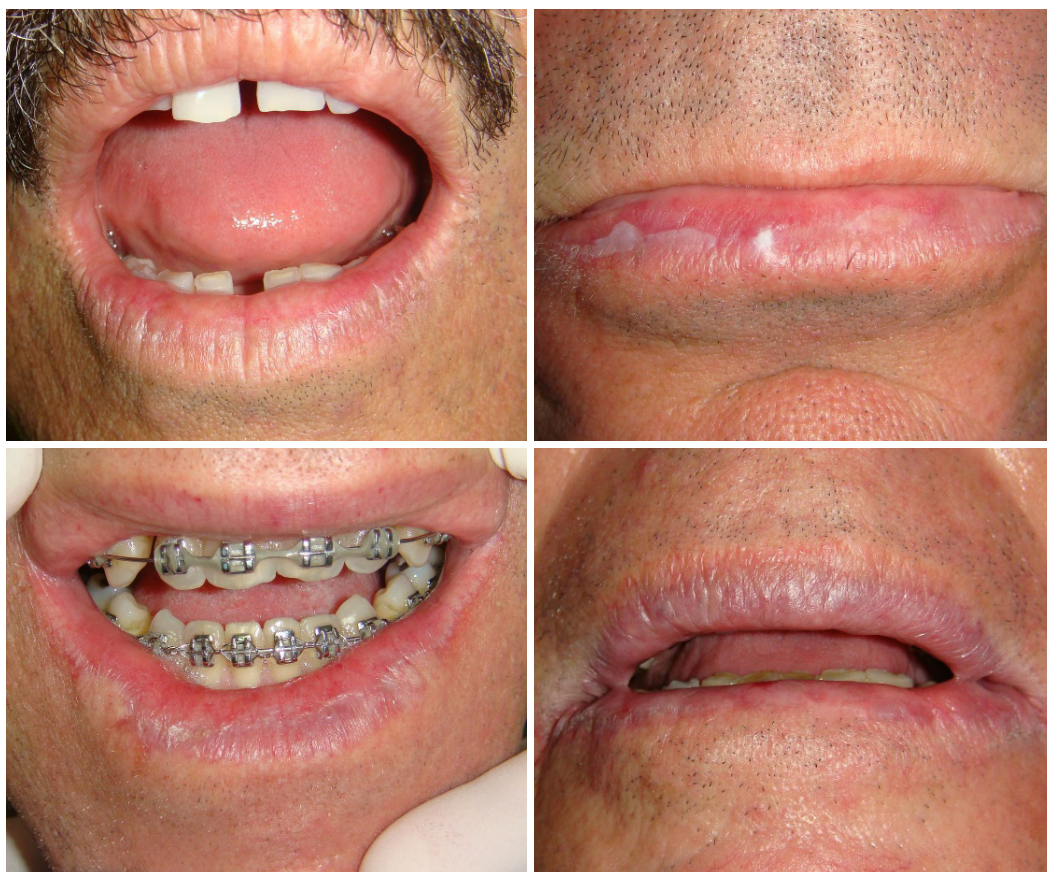

Figure 1: Clinical photos of actinic cheilitis (AC) reference for applying the Poitevin classification, 2017 – **A:** AC grade I - fissure and desquamation; **B:** AC grade II - atrophy of the vermilion lip, leukoerythroplastic and brown color changes, shallow fissures and beginning to lose definition of the boundary between lip and skin; **C:** AC grade III - rough, dry and hyperkeratotic regions; and **D:** AC grade IV - change in color throughout the lip, deep fissures and swollen lip appearance, with a heterogeneous leukoerythroplastic lesion speckled on the right, suggestive of malignancy.

It is important to highlight that, although there are classifications that facilitate therapeutic decisions, there are a variety of clinical presentations for the different degrees of AC. Therefore, initial clinical signs should not be ignored, since the presence of lesions that appear clinically homogeneous do not correlate with the degree of histological alteration (21, 24). Clinical findings alone should also not be considered as decisive factors for whether a biopsy should be indicated (37).

In cases in which AC is clinically harmless, conservative treatment is the most indicated, especially the use of lip sunscreen. Biopsy is indicated according to the clinical aspects of the disease and with the aim of monitoring the patient for possible malignant transformation of

the lesion. After the biopsy, in cases of absence of epithelial dysplasia, conservative treatment can be applied, and the patient must be instructed to use adequate protection, in the form of lip sunscreen and a brimmed hat. However, patients in whom exposure to sunlight is continuous should undergo regular monitoring and more cautious care (35).

For better clinical management, it is necessary to carry out a clinical assessment (30), in which anamnesis must be applied, containing the clinical history of the injury, the clinical examination itself and the correct referral to the specialist, if necessary, to perform a biopsy with histopathological evaluation (35). In the flowchart presented in the Figure 2, it is possible to check the relevant points to be considered in the clinical assessment.

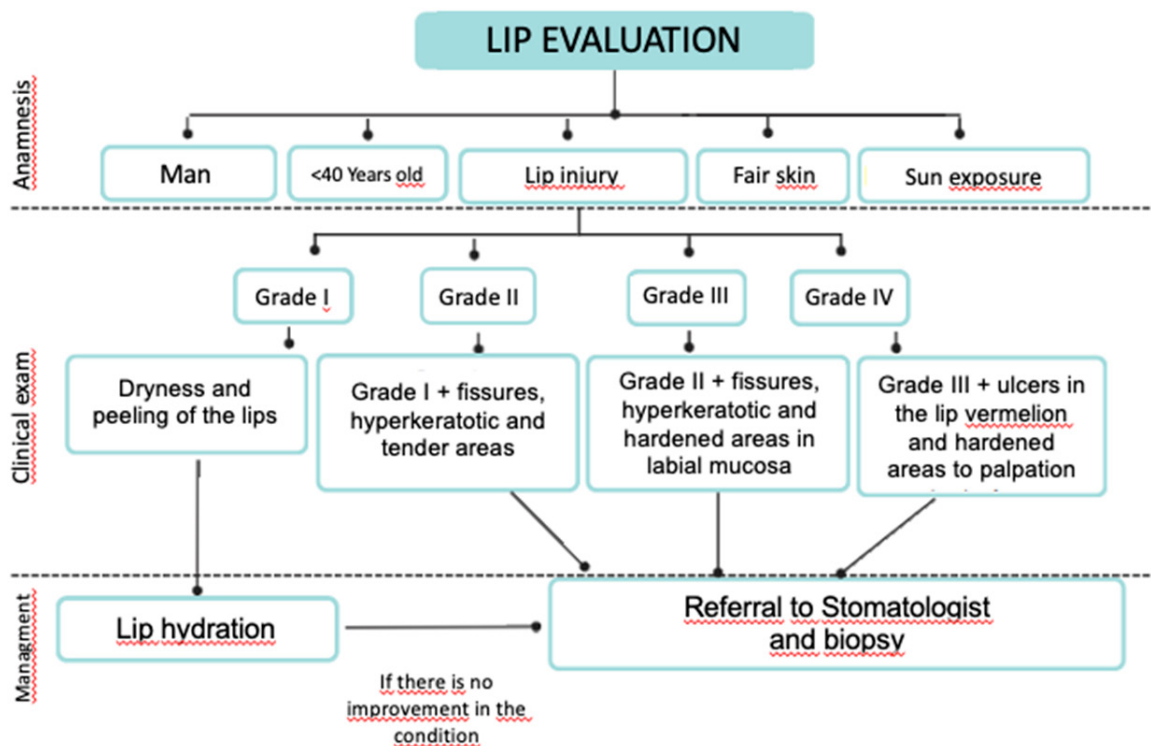


Figure 2: Flowchart containing the relevant characteristics of the anamnesis that suggest the presence of AC, as well as the signs present in the clinical examination and management in each of these conditions. (Adapted by Poitevon et al., 2017).

The prognosis of AC depends not only on histological characteristics, but also on the patient's change in habits, as well as their commitment to treatment (21). The exact rate of transition from AC to carcinoma is still unknown, however, it is known that AC more than doubles the patient's risk of developing SCC of the lip (19, 30).

Patient instructions

Even though many of the changes associated with AC are irreversible, patients should be encouraged to reduce sun exposure, especially between 10 am

and 2 pm, and 3 pm during daylight hours, wear a wide-brimmed hat and lip sunscreen to prevent further damage (19, 30). Still regarding the use of sunscreen, studies show that those who reapply sunscreen during exposure to the sun have a lower risk of developing the pathology (38).

Mild cases must be evaluated regularly to prevent malignant transformation of the lesion (35). In the early stages, without mild changes or dysplasia, treatment is the use of lip sunscreens. Thus, to prevent skin and lip cancer, patients should use sun protection factor 15 or greater,

requiring reapplication throughout the day (39, 40), in addition to remaining in the shade, wearing protective clothing and not use industrial tanning devices (39).

CONCLUSION

Male individuals, with an average age of 40 years, with fair skin and who are constantly exposed to the sun, are considered a risk group for the development of AC. The clinical and histopathological characteristics of AC must be considered by the dentist to intervene as early as possible and exclude the possibility of a diagnosis of SCC of the lip. The use of individual photoprotection barriers and lip sunscreen are the most efficient way to prevent the onset of AC.

The authors declare no conflicts of interest.

Corresponding author:

Maria Vitória de Mattos
Av. Epitacio Pessoa 2800/1003
22471003
mariavitoriamattos19@gmail.com

REFERENCES

1. De Oliveira Santos M. Estimativa/2020 – Incidência de Câncer no Brasil. Rev. Bras. Cancerol. [Internet]. 2020;66(1):e-00927.
2. Warnakulasuriya S, Johnson NW, Van Der Waal I. Nomenclature and classification of potentially malignant disorders of the oral mucosa. Journal of Oral Pathology and Medicine. 2007; J Oral Pathol Med. 2007 Nov;36(10):575-80.
3. Moy RL. Clinical presentation of actinic keratoses and squamous cell carcinoma. J Am Acad Dermatol. 2000 Jan;42(1 Pt 2):8-10.
4. Speight PM, Khurram SA, Kujan O. Oral potentially malignant disorders: risk of progression to malignancy. Oral Surgery, Oral Medicine, Oral Pathology and Oral Radiology; 2018 Jun;125(6):612-627.
5. Campisi G, Margiotta V. Oral mucosal lesions and risk habits among men in an Italian study population. J Oral Pathol Med. 2001 Jan;30(1):22-8.
6. Rodríguez-Blanco I, Flórez Á, Paredes-Suárez C, Rodríguez-Lojo R, González-Vilas D, Ramírez-Santos A, Padela S, Suárez Conde I, Pereiro-Ferreirós M. Actinic Cheilitis Prevalence and Risk Factors: A Cross-sectional, Multicentre Study in a Population Aged 45 Years and Over in North-west Spain. Acta Derm Venereol. 2018 Nov 5;98(10):970-974
7. De Visscher JGAM, Van Der Waal I. Etiology of cancer of the lip: A review. Int J Oral Maxillofac Surg. 1998 Jun;27(3):199-203.
8. Wolf ST, Kenney LE, Kenney WL. Ultraviolet Radiation Exposure, Risk, and Protection in Military and Outdoor Athletes. Curr Sports Med Rep. 2020 Apr;19(4):137-141
9. Dancyger A, Heard V, Huang B, Suley C, Tang D, Ariyawardana A et al. Malignant transformation of actinic cheilitis: A systematic review of observational studies. J Investig Clin Dent. J Investig Clin Dent. 2018 Nov;9(4):e12343.
10. Piñera-Marques K, Lorenço SV, da Silva LFF, Sotto MN, Carneiro PC. Actinic lesions in fishermen's lower lip: Clinical, cytopathological and histopathologic analysis. Clinics (Sao Paulo). 2010 Apr;65(4):363-7.
11. Arnaud RR, Soares MSM, Paiva MAF de, Figueiredo CRLV de, Santos MGC dos, Lira CC. Queilite actínica: avaliação histopatológica de 44 casos. Rev Odontol UNESP. 2014 Nov.-Dec.; 43(6): 384-389.
12. Markopoulos A, Albanidou-Farmaki E, Kayavis I. Actinic cheilitis: clinical and pathologic characteristics in 65 cases. Oral Surgery, Oral Med Oral Pathol Oral Radiol Endodontology. Oral Dis. 2004 Jul;10(4):212-6
13. Miranda AMO, Soares LG, Ferrari TM, Silva DG, Falabella MEV, Tinoco EMB. Prevalence of actinic cheilitis in a population of agricultural sugarcane workers. Acta Odontol Latinoam. 2012;25(2):201-6
14. Picascia DD, Robinson JK. Actinic cheilitis: A review of the etiology, differential diagnosis, and treatment. J Am Acad Dermatol. 1987 Aug;17(2 Pt 1):255-64.
15. Brito LNS, Bonfim ACE da A, Gomes DQ de C, Alves PM, Nonaka CFW, Godoy GP. Clinical and histopathological study of actinic cheilitis. Rev odontol UNESP [Internet]. 2019;48:e20190005.
16. Queilite Actínica: Aspectos Clínicos e Prevalência Encontrados em Uma População Rural do Interior do Brasil. Saúde e Pesquisa.; v. 4 n. 1 (2011): jan./abr.
17. Silva LV de O, de Arruda JAA, Abreu LG, Ferreira RC, da Silva LP, Pelissari C, et al. Demographic and Clinicopathologic Features of Actinic Cheilitis and Lip Squamous Cell Carcinoma: a Brazilian Multicentre Study. Head Neck Pathol. 2020 Dec;14(4):899-908.
18. Mello FW, Melo G, Modolo F, Rivero ERC. Actinic cheilitis and lip squamous cell carcinoma: Literature review and new data from Brazil. J Clin Exp Dent. 2019 Jan 1;11(1):e62-e69.
19. Neville BW, Damm DD, Allen CM, Bouquot JE. Patologia Oral e Maxilofacial. Patologia Oral e Maxilofacial. 2016.
20. Abreu MAMM de, Silva OMP da, Neto Pimentel DR, Hirata CHW, Weckx LLM, Alchorne MM de A, et al.. Queilite actínica adjacente ao carcinoma espinocelular do lábio como indicador de prognóstico. Rev Bras Otorrinolaringol [Internet]. 2006 Nov;72(6):767-71.
21. de Santana Sarmiento DJ, da Costa Miguel MC, Queiroz LMG, Godoy GP, Da Silveira ÉJD. Actinic cheilitis: Clinicopathologic profile and association with degree of dysplasia. Int J Dermatol. 2014 Apr;53(4):466-72.
22. Kaugars GE, Pillion T, Svirsky JA, Page DG, Burns JC, Abbey LM. Actinic cheilitis a review of 152 cases. Oral Surg Oral Med Oral Pathol Oral Radiol Endod. 1999 Aug;88(2):181-6.
23. Cavalcante ASR, Anbinder AL, Carvalho YR. Actinic Cheilitis: Clinical and Histological Features. J Oral Maxillofac Surg. 2008 Mar;66(3):498-503.

24. Jadotte YT, Schwartz RA. Solar cheilosis: An ominous precursor: Part I. Diagnostic insights. Diagnostic insights. *J Am Acad Dermatol*. 2012 Feb;66(2):173-84.
25. De Souza Lucena EE, Costa DCB, Da Silveira EJD, Lima KC. Prevalence and factors associated to actinic cheilitis in beach workers. *Oral Dis*. 2012 Sep;18(6):575-9.
26. Camargo MB, Dumith SC, Barros AJ. Uso regular de serviços odontológicos entre adultos: padrões de utilização e tipos de serviços. *Cad Saude Publica*. 2009 Sep;25(9):1894-906.
27. Martins-Filho PRS, Da Silva LCF, Piva MR. The prevalence of actinic cheilitis in farmers in a semi-arid northeastern region of Brazil. *Int J Dermatol*. 2011 Sep;50(9):1109-14.
28. Main JH, Pavone M. Actinic cheilitis and carcinoma of the lip. *J Can Dent Assoc*. 1994 Feb;60(2):113-6
29. Baldes IP, Azevedo AB, Macedo JC, Silami MANC, Penoni DC, Andrade MAC. Queilite actínica: análise retrospectiva de 29 casos da Clínica de Estomatologia da Odontoclínica Central da Marinha. *Rev Nav Odontol*. v. 43 n. 1 (2016).
30. Lugović-Mihić L, Pilipović K, Crnarić I, Šitum M, Duvančić T. Differential diagnosis of cheilitis – How to classify cheilitis? *Acta Clinica Croatica*. 2018 Jun;57(2):342-351.
31. Martins MD, Marques LDO, Martins MAT, Bussadori SK, Fernandes KPS. Queilite actínica: relato de caso clínico. *ConScientiae Saúde*. 2007; 6 (1): 105-110.
32. Lopes MLD de S, da Silva Júnior FL, Lima KC, de Oliveira PT, da Silveira ÉJD. Clinicopathological profile and management of 161 cases of actinic cheilitis *An Bras Dermatol*. 2015 Jul-Aug;90(4):505-12.
33. Campisi G, Margiotta V. Oral mucosal lesions and risk habits among men in an Italian study population. *J Oral Pathol Med*. 2001 Jan;30(1):22-8.
34. Purim KS, Leite N. Sports-related dermatoses among road runners in Southern Brazil. *An Bras Dermatol*. 2014 Jul-Aug;89(4):587-92.
35. Savage NW, McKay C, Faulkner C. Actinic cheilitis in dental practice. *Aust Dent J*. 2010 Jun;55 Suppl 1:78-84.
36. Poitevin NA, Rodrigues MS, Weigert KL, Macedo CLR, dos Santos RB. Actinic cheilitis: proposition and reproducibility of a clinical criterion. *BDJ Open*. 2017 Aug 4;3:17016.
37. Seoane J, Warnakulasuriya S, Bagán JV, Aguirre-Urizar JM, López-Jornet P, Hernández-Vallejo G, González-Moles MÁ, Pereiro-Ferreiros M, Seoane-Romero J, Varela-Centelles P. Assembling a consensus on actinic cheilitis: A Delphi study. *J Oral Pathol Med*. 2021 Nov;50(10):962-970.
38. Rodríguez-Blanco, I., Florez, Á., Paredes-Suárez, C., Rodríguez-Lojo, R., González-Vilas, D., Ramírez-Santos, A., Pereiro-Ferreirós, M. Use of lip photoprotection in patients suffering from actinic cheilitis. *Eur J Dermatol*. 2019 Aug 1;29(4):383-386.
39. Rodrigues F, Mármora B, Carrion SJ, Segalla DB, Pospich FS RA. Uso de protetores solares na prevenção do carcinoma de células escamosas em lábio (2016). Uso de protetores solares na prevenção do carcinoma de células escamosas de lábio. *Journal Health NPEPS*, 1(1).
40. Bruzzzone R, Vanzulli S.L MR. Queilite actínica crônica: caso clínico. *Rev. Círc. Argent. Odontol* ; 25(178): 25-7, jun. 1996.